

Making Waves

by Joseph Niamtu III, DDS



Radiowave surgery offers laser-like outcomes in facial cosmetic procedures, but with precision cutting and a faster healing process

Laser technology has certainly advanced cosmetic facial surgery by leaps and bounds. Only 7 years ago, many of today's standard techniques were not available. Skin resurfacing, endoscopic assisted surgery, laser blepharoplasty, and lesion removal are only a few of the procedures that laser technology has revolutionized or improved.

Electrosurgery has been around since the inception of electricity. Early electrosurgery units were no more than sophisticated soldering irons that heated an electrode like the coil in a toaster to sear tissue. Advances in electrical engineering in the early 1900s soon allowed electrodesiccation and fulguration by using a spark gap to destroy lesions or cauterize bleeding. The problem was increased lateral tissue destruction.

In the 1920s and 1930s, continued improvement created bipolar systems, which are the basis for hospital operating room units used today. These units transfer electrical energy to the electrode and through the patient to a grounding electrode. These units are capable of cutting and coagulation, and although more refined, still cause the electrode to heat and

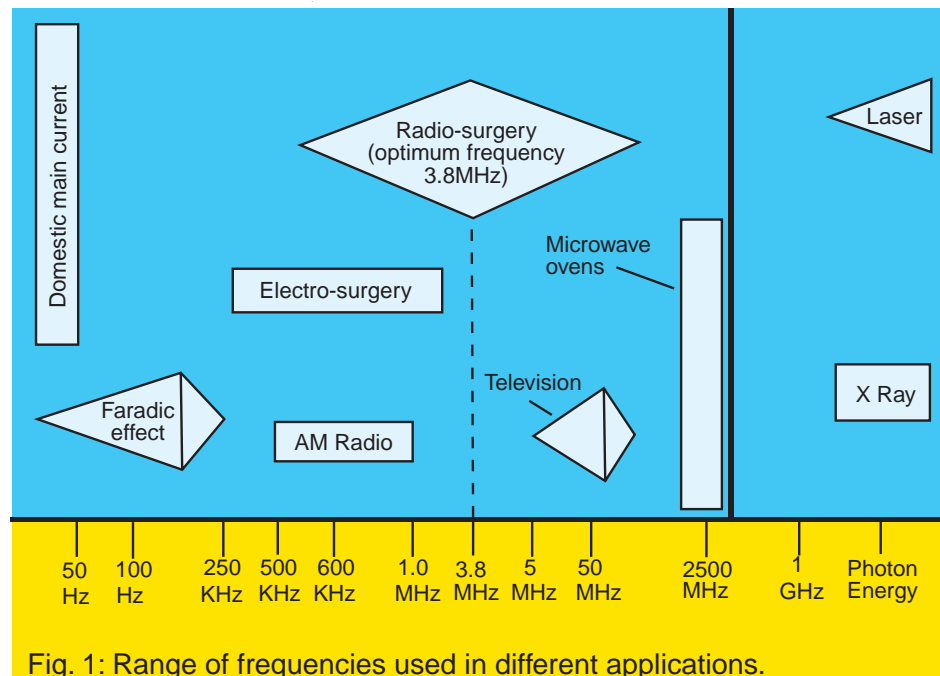


Fig. 1: Range of frequencies used in different applications.

Figure 1. Contemporary radiowave surgery uses a frequency of 4.0 MHz, which is similar to the frequency of marine band radio.

Making Waves

cause significant lateral tissue damage.

Radiowave surgery is a completely different concept from electrocautery or diathermy machines. Radiowave units operate on a standard 60-cycle household current and convert to a high frequency wave of 4.0 MHz, which is similar to the frequency of marine band radios (Figure 1, page 52).

How it Works

What is truly unique about radiowave surgery is that the electrode does not offer resistance, and therefore, is not heated. The tissue offers the resistance, which causes intracellular boiling and volatilization that results in cutting or coagulation. With radiowave units, high frequency radiowaves are transferred from the unit to the tissue, and are then collected by an antenna and recycled back to the machine. The antenna plate used in radiowave surgery functions like an antenna on a cellular phone—collecting energy from the patient. Since it functions like a true antenna and not a grounding plate, bare skin contact is unnecessary, and there is no opportunity to shock or burn the patient or operator.

The wave form of the radiowave unit can be altered for a pure cutting current (fully rectified), which has the least amount of lateral tissue damage, a cutting and coagulation mode (par-

When scalpels are used on thin tissue such as the eyelid, there is a tendency to drag, whereas the fine radiowave electrode glides with minimal contact in a nearly laser-like manner.

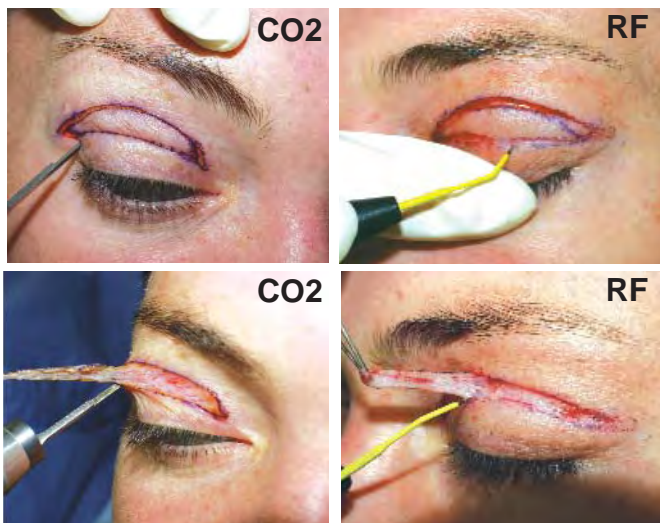


Figure 2. The top left image shows bloodless skin incision with a CO2 Laser 0.02 mm handpiece, while top right image shows a similarly bloodless skin incision with a radiowave surgery unit and a micro-needle.

The lower left image shows the skin dissection with a CO2 laser and the lower right image shows the same patient's dissection with the radiowave surgery unit. Note the lack of bleeding is virtually the same with both modalities.

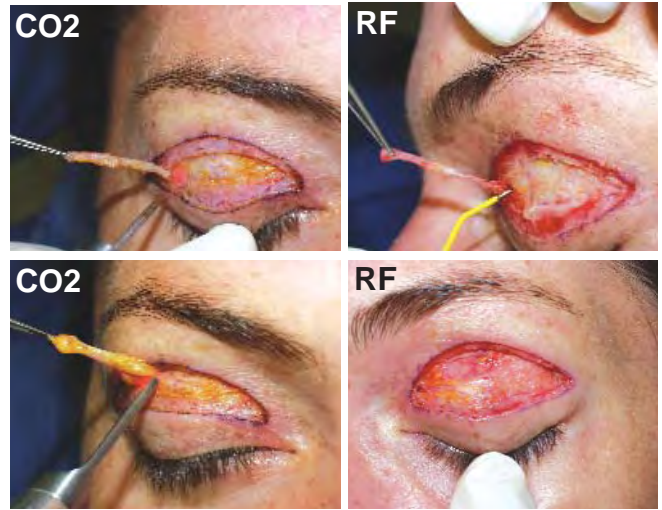


Figure 3. The top images show orbicularis muscle strip excision with the CO2 laser and radiowave surgery unit. The lower images show the virtually bloodless surgical fields after peri-orbital fat removal. This type of excellent hemostasis is achievable with either modality.

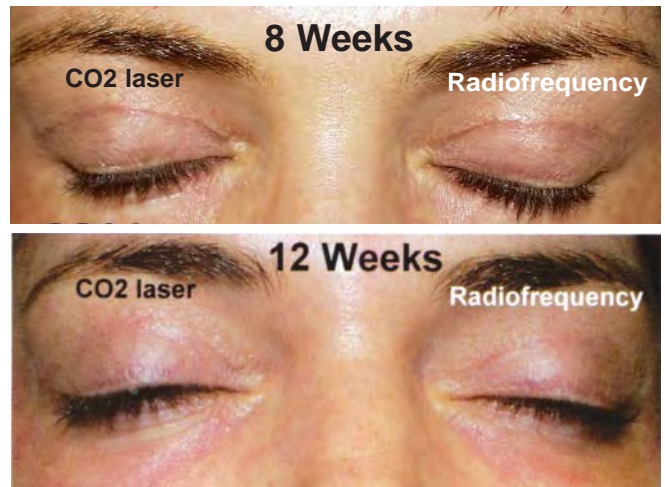


Figure 4. The upper images show the CO2 (left) and radiowave (right) scars at 8 weeks postoperative. The lower images show same patient at 12 weeks postoperative. The radiowave incision looks slightly better at 8 weeks, while both incisions are equal at 12 weeks.

tially rectified), a pure coagulation mode, and a fulguration mode. In addition, these systems have a bipolar mode for coagulation.

Multiple studies have shown that radiowave surgery is comparable or superior to lasers for incision, biopsy, and lateral tissue damage.¹⁻⁵ Less tissue damage means faster healing, and less scarring and discomfort. Furthermore, radiowave surgery offers advantages over scalpel incision, including a combined cutting and coagulation, and an increased tactile ability and a pressureless incision. When scalpels are used on thin tissue such as the eyelid, there is a tendency to drag, whereas the fine radiowave electrode glides with minimal contact in a nearly laser-like manner. Finally, the energized radiowave electrode is self-sterilizing.

Laser vs Radiowave

The following images illustrate the use of radiowave surgery and CO2 Laser for upper lid blepharoplasty on the same patient as a control.

The images in Figure 2 show the skin incision on the right lid with a CO2 laser, and on the left lid with a radiowave surgery

Making Waves

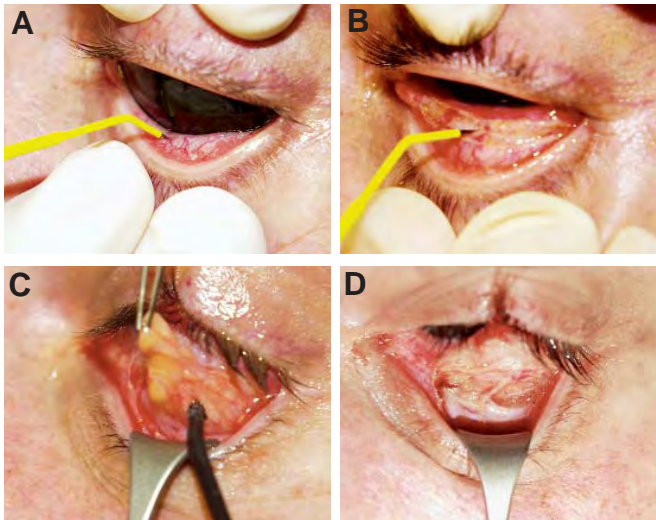


Figure 5A shows the position of the radiowave incision with the Ellman Microneedle, which is approximately 4 mm inferior to the tarsal margin. **Figure 5B** shows the incision through the conjunctiva and capsulopalpebral fascia. Note the lack of bleeding in these vascular areas. **Figure 5C** shows the Ellman small ball electrode simultaneously incising and cauterizing the base of the herniated periorbital fat. **Figure 5D** shows the bloodless surgical field after radiowave blepharoplasty.

unit and a microneedle. Note the bloodless field on both incisions.

The upper images in Figure 3 (page 54) show a strip orbicularis muscle excision with both modalities, while the lower images in Figure 3 illustrate fat resection with both modalities. Again, there is little difference between laser and radiowave incision.

Figure 4 (page 54) shows the healing incisions at 8 and 12 weeks respectively. In terms of healing, the incisions are basically indistinguishable.

Radiowave surgery is also well suited for transconjunctival blepharoplasty. It offers the same advantages of pressureless incision, decreased bleeding, and reduced traction of periorbital fat.

Figure 5A and 5B show the microneedle incising the conjunctiva and capsulopalpebral fascia with a bloodless incision. Figure 5C shows the herniated periorbital fat being gently retracted with a tissue forceps and a small ball electrode incising and coagulating its base. Using radiowave surgery for this in lieu of hemostat clamping, not only reduces the traction on the fat pads but also allows direct vi-

sion and excellent vessel coagulation. The intraoperative feel and result are very similar to the CO₂ laser. Figure 5C shows the bloodless surgical field after periorbital fat removal.

I have performed laser and radiowave blepharoplasty on more than 200 eyelids, and both techniques work equally well. The obvious advantage of purchasing a radiowave surgery unit versus a laser is the cost savings. Additionally, the radiowave unit weighs less than 30 lbs and is extremely portable. Another advantage of the radiowave system is that there are less hazards and precautions than the laser. Most surgeons who use lasers for blepharoplasty are familiar with the problems of incidental

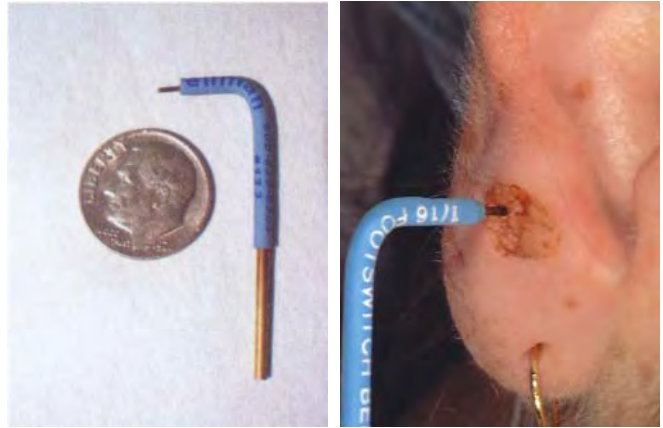


Figure 7. Flat tipped or ball electrodes are well suited for lesion removal. The tissue is removed layer by layer under loupe visualization in a manner very similar to laser ablation.

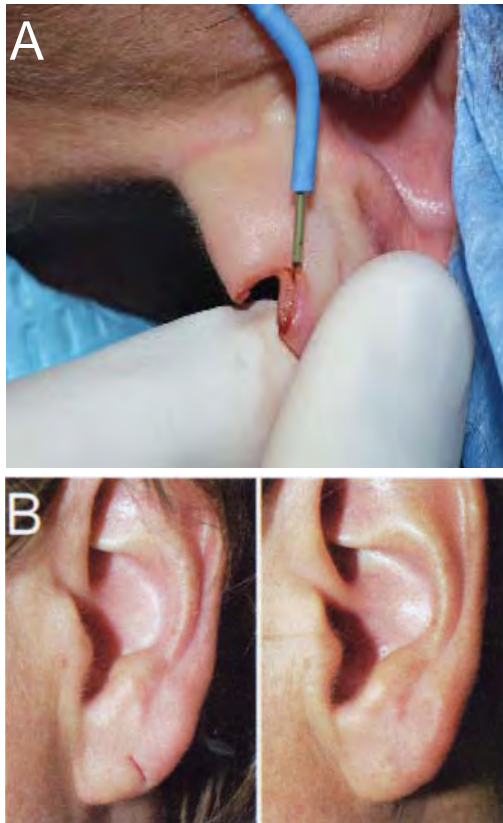


Figure 6A. The electrode is well suited for precision incision with little pressure for mobile of fleshy anatomy such as the earlobe. **Figure 6B** shows the excellent healing with radiowave surgery.

laser beams that can inadvertently burn the adjacent tissues when passing through the intended tissue. For instance, protective instruments must be used to protect the bridge of the nose when cutting through medial eyelid tissue as the beam does not stop at the excised tissue margin.

There is also the problem of laser beam reflection on unwanted areas of the patient and operator. Other concerns that surgeons have when operating lasers are the safety of other personnel in the room and the fire hazard of misguided laser beams. Although I use lasers frequently for a variety of cosmetic facial procedures, radiowave technology is clinically similar to the CO₂ laser and can provide laser-like intraoperative and postoperative results.

Radiowave Applications

Other cosmetic applications that are facilitated with radiosurgery include lesion removal, biopsy, and earlobe repair. Due to the physics of radiosurgery, the electrode tip does not offer the electrical resistance, hence, it glides very smoothly through tissue. As previously mentioned, this is a distinct advantage when incising mobile tissues such as eyelid skin, oral mucosa, and fleshy cutaneous anatomy. Another advantage of radiosurgery is that malleable electrodes are available that can be conformed to accommodate any surgical position. This is especially helpful when working in a cavity or in the lower eyelid in transcon-

Making Waves

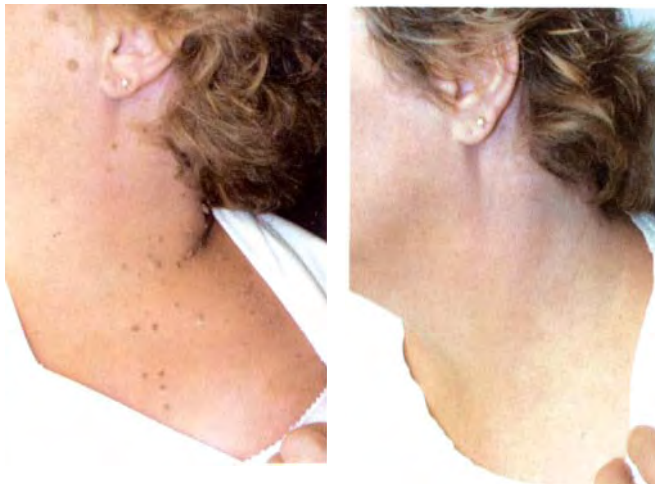

Figure 8 shows excellent healing on the neck and face.

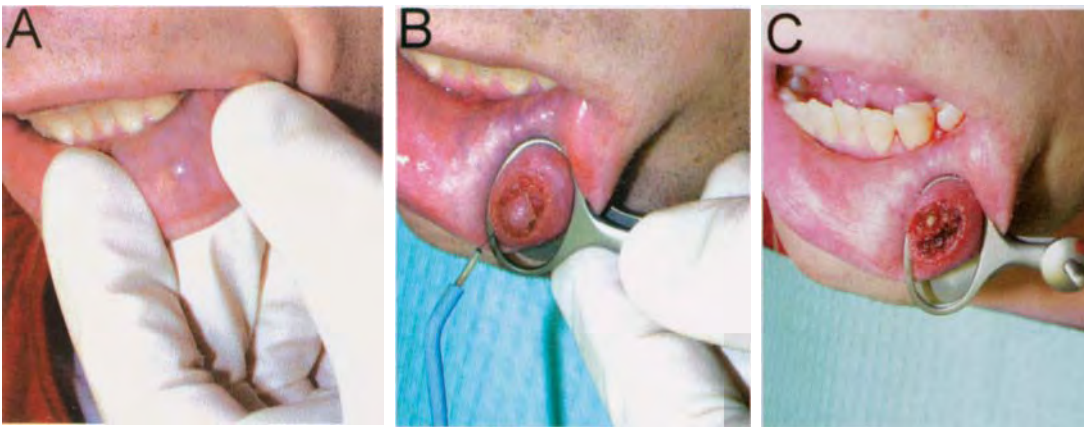


Figure 9A shows a lesion of the lower lip. 9B shows the incision using the electrode with a pure cutting current. 9C shows an area of fulguration and cauterization of tissue bleeders. Excellent hemostasis is achievable with radiosurgery.

junctional blepharoplasty.

Figure 6A (page 56) shows the use of a needle electrode for the repair of a torn earlobe. Figure 6B shows excellent healing after radiosurgery. Since the earlobes are fleshy and mobile, the pressureless incision of radiosurgery is well suited for this anatomy.

Figure 7 (page 56) shows the removal of a benign nevus using a radiowave flat-tipped electrode. Figure 8 again shows the excellent healing of radiosurgery in the excision of multiple nevi.

One problem with using traditional electro-surgery for biopsy is the severe tissue artifact often seen from lateral heat damage. Since the radiowave unit allows for the selection of specific wave forms, a lesion can be excised with a low, pure

cutting current and experience virtually no artifact,^{3,4} thus, not impeding the histopathologic diagnosis.

Figure 9A shows a lesion on the lower lip. This is a very vascular area with mobile mucosa. Radiowave surgery is ideal for this type of situation because of the pressureless incision and the great hemostasis of simultaneous cutting and coagulation. Since a biopsy is planned, the initial incision is made with a pure cutting current, which will leave little thermal artifact (Figure 9B). The cut/coag mode is then employed for the resection of the lesion and provides excellent hemostasis for the muscle and other vascularized tissue associated with the lesion (Figure 9C). In addition, the pure coagulation mode is convenient to cauterize bleeding vessels or to fulgurate remaining pathologic tissue.

Although surgical incision with electric current is not a new concept, radiosurgery has made significant advances in technology. This technology has provided cosmetic surgeons

with multiple advantages including precision cutting, selectable modes, excellent hemostasis, pressureless incision, and faster healing.

Radiowave surgery has been shown to rival laser and cold steel methods for healing and precision and should be in the armamentarium of all surgeons. ■

[Radiowave surgery] has provided cosmetic surgeons with precision cutting, selectable modes, excellent hemostasis, pressureless incision, and faster healing.

About the Author

Joseph Niamtu III, DDS, is in group private practice of Oral and Maxillofacial Surgery in Richmond, Va. He is board certified by the American Board of Oral and Maxillofacial Surgery and a fellow of the American Academy of Cosmetic Surgery and the American College of Oral and Maxillofacial Surgeons. He can be contacted via email: niamtu@niamtu.com.

References

1. Niamtu J. Oral and Maxillofacial Surgical Clinics of North America. *Cosmetic Facial Surgery*. 2000;12:771-80.
2. Saidi MH, Setzler FD, Sadler KR, Farhart SA, Akright BD. Comparison of office loop electro-surgical conization and cold knife conization. *Journal of the American Association of Gynecologic Laparoscopists*. 1994;1:135-139.
3. Turner RJ, Cohen RA, Voet RL, Stephans SR, Weinstein SA. Analysis of tissue margins of cone biopsy specimens obtained with "cold knife" CO₂ and Nd: YAG lasers and a radiofrequency surgical unit. *Journal of Reproductive Medicine*. 1992;37(7):607-610.
4. Kalwarf KL, Kreici FR, Edison AR, Reinhardt RA. Lateral heat production secondary to electro-surgical incisions. *Oral Surg Oral Med Oral Pathol*. 1983;55(4):344-8.
5. Hurwitz JJ, Johnson D, Howarth D, Molgat M. High-frequency radio wave electrosection of full-thickness eyelid tissues. *Can J Ophthalmol*. 1992;28:28-31.