

Radiophonosurgery of benign superficial vocal fold lesions

SAMEH M RAGAB, MS, MD, FRCSED, MOHAMED N ELSHEIKH, MS, MD, MAGDY E SAAFAN, MS, MD, SAYED G ELSHERIEF, MS, MD

Abstract

Objective: To conduct a prospective randomized controlled trial describing and investigating the efficacy and safety of radiosurgical excision of benign superficial vocal fold lesions.

Materials and methods: Fifty patients with benign superficial vocal fold lesions (20 vocal nodules, 27 vocal polyps and three Reinke's oedema) who failed conservative therapy were included in the study. They were equally randomized into cold knife or radiosurgical excision. Clinical and voice assessments were done pre-operatively and after surgery. Voice analysis included a subjective visual analogue scale (VAS) and a perceptual assessment with a simplified version of the GRBAS scale (GRB) consisting of G (grade), R (roughness), and B (breathiness). Acoustic voice evaluation included jitter and shimmer. Post-operative voice therapy was provided for all patients. Complications, smoothness of post-operative recovery, and administration of analgesia were reported.

Results: Both groups experienced significant improvement in VAS, perceptual evaluation and acoustic analysis after surgery, with no evidence of significant differences between the cold knife and radiofrequency groups. The radiofrequency group showed a decrease of 17 per cent in the mean operative time when compared with the cold knife group, but this was not statistically significant. No evidence of a significant difference was noticed in the smoothness of post-operative recovery, administration of analgesia and complication rate.

Conclusion: Radiophonosurgery opens a new therapeutic approach for patients with benign superficial vocal fold lesions. It combines the advantages of both cold knife and laser phonosurgery, being easy, safe, precise and effective, and having excellent tactile and haemostatic properties.

Key words: Cold Knife; Radiofrequency; Phonosurgery; Vocal Nodule; Vocal Polyp; Reinke's Oedema; Vocal Cord; Randomized; Prospective; Controlled

Introduction

Benign superficial lesions of the vocal fold (nodule, polyp, cyst and Reinke's oedema) arise from the epithelium and the lamina propria. Vocal overuse, abuse and misuse presumably lead to excessive mechanical stress and trauma in the membranous portion of the vocal fold, resulting in wound formation. Wound healing leads to remodelling of the superficial layer of the lamina propria and, to a lesser extent, the vocal fold epithelium. This tissue remodelling leads to the formation of a benign vocal fold lesion. Several studies have demonstrated that the pathological changes in benign vocal fold lesions occur within the superficial layer of the lamina propria. However, the exact mechanism of formation of a particular type of lesion remains incompletely understood.¹

The first transoral excision of a laryngeal polyp was done by Horace Green in 1852. However, Kirnstein (1895) is generally considered the first to have performed direct laryngoscopy. Killian (1911)

introduced the suspended laryngoscope, which was developed three years later by Lynch. In 1954, Albrecht adapted the microscope for use in laryngeal surgery.² The development of 400 mm lenses improved the working distance and enhanced microlaryngoscopic surgery remarkably. In 1963 Hans von Leden and Godfrey Arnold agreed to designate functional laryngeal surgery phonosurgery, with the maintenance and improvement of vocal function, as the goals of phonosurgeons. The conventional technique was developed from 1964 by Kleinsasser.³ In 1972, endoscopic laryngeal microsurgery using a carbon dioxide laser was established by Jako and Strong.⁴

Electrosurgical units operate using the fundamental principles of physics by involving the passage of electrical current through tissue to create the desired tissue effect. The probe does not heat, as in electrocautery; rather, the tissue heats in response to the radiofrequency current passing through it. The electrosurgical circuit includes the




FIG. 1

The radiosurgical probe fashioned by the authors.

radiofrequency generator, active electrode, grounding pad, and the patient. It produces five distinct waveforms; fully filtered, fully rectified, partially rectified, fulguration and bipolar. Each of these modes uses a combination of frequency, power, waveform, electrode size and time of application to produce a tissue temperature which will result in a predictable histological effect. Radiofrequency has been used in gynaecological, plastic, surgical and dermatological practice for more than 30 years and is a well-established and valuable tool in these fields of medicine. In otolaryngology, it has been used in palatal, turbinate and tonsillar reduction, taking advantage of its ablative and haemostatic properties.^{5,6} Recently, the authors of the current trial demonstrated the use of radiofrequency in posterior transverse cordotomy for bilateral median vocal fold immobility.⁷ However, there is no report in the literature

discussing its use in benign superficial vocal fold lesions.

Therefore this study was conducted in a prospective randomized controlled fashion to describe and investigate the efficacy and safety of radiosurgical excision of benign superficial vocal fold lesions.

Materials and methods

Patients were recruited over two years from the otolaryngology clinics of Tanta University Hospitals, Egypt. The study protocol and consent forms were approved by the research review committee. After application of the exclusion criteria, the study was discussed with 67 consecutive patients with a clinical diagnosis of benign superficial vocal fold lesions (vocal fold nodules, polyps and Reinke's oedema). All patients had a trial of conservative medical and voice therapy. They were also asked to stop

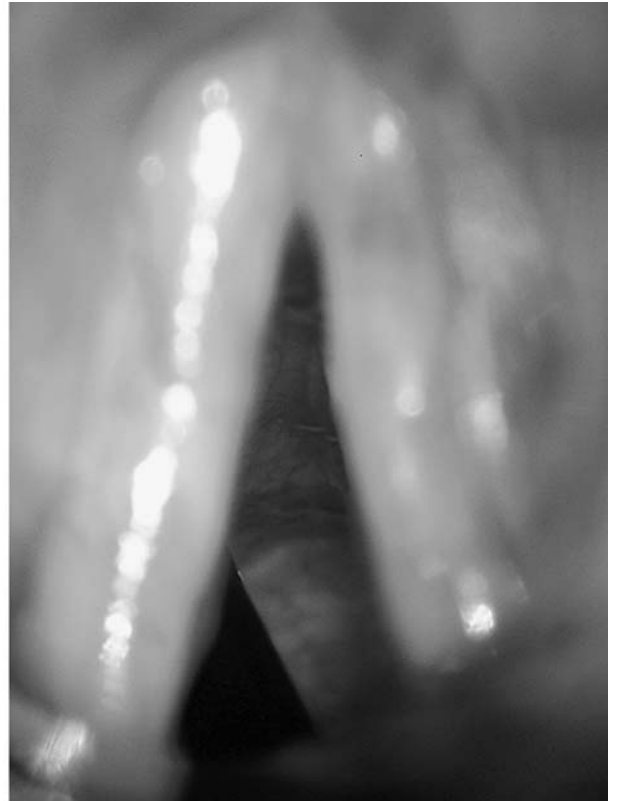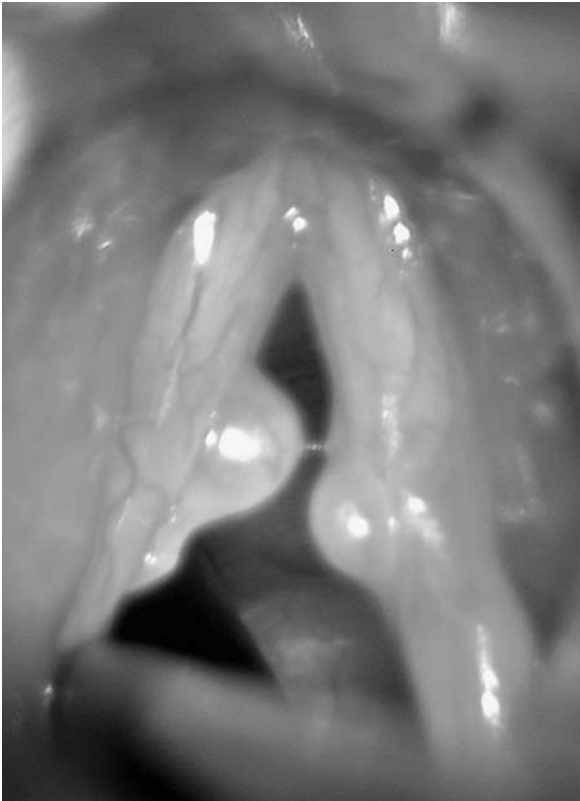


FIG. 2

Pre- and post-radiosurgical excision of bilateral vocal fold nodules.

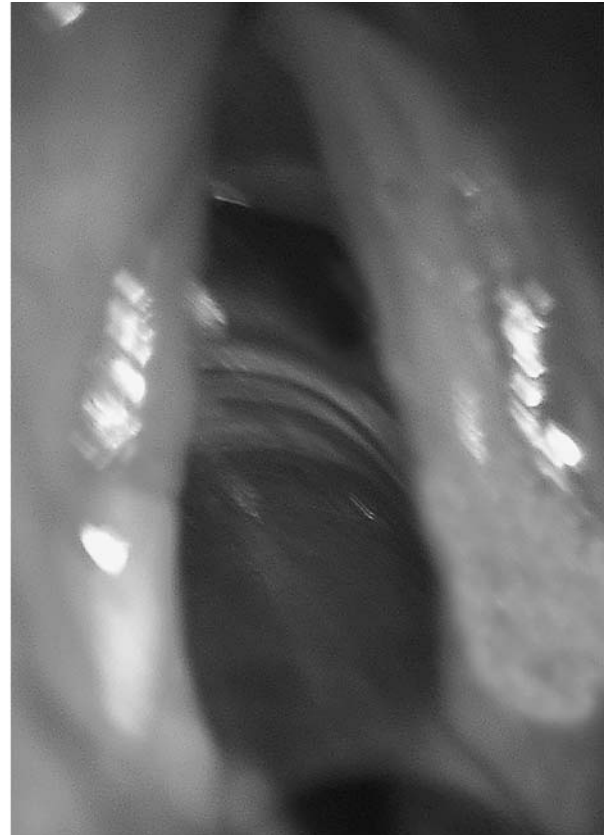
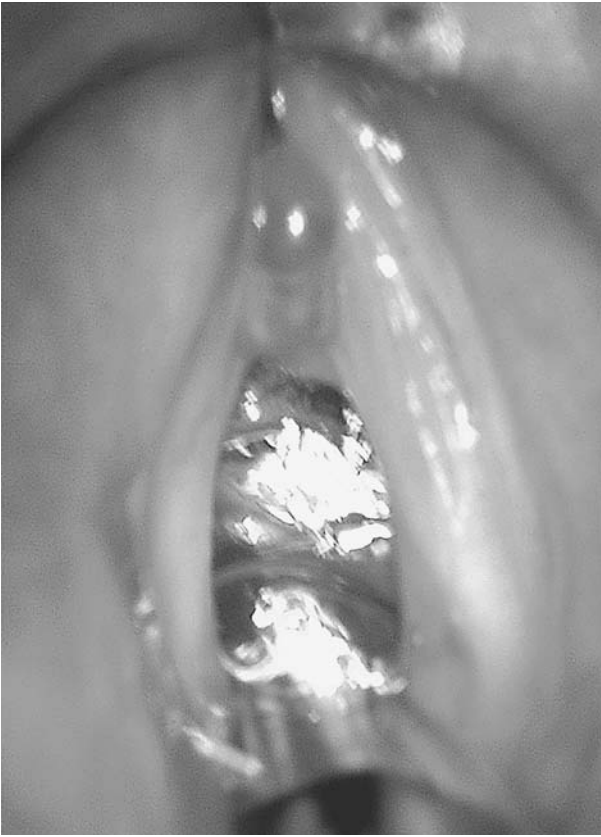

FIG. 3

Pre- and post-radiosurgical excision of a vocal fold polyp.

smoking. Of these, 50 patients who agreed to the process of randomization and failed the conservative therapy finally consented to be included in the study. The patients were equally randomized into two groups: cold knife and radiofrequency. The exclusion criteria included pregnancy, lactation, significant psychological problems, inability to comply with the study protocol, being aged below 18 years, inability to tolerate surgery with general anaesthesia due to concurrent medical conditions, and other medical and/or surgical treatments influencing the study. The study comprised 27 males and 23 females, with a mean age \pm (SD) of $37 \pm (12)$, vocal fold nodules (nine cold knife and 11 radiofrequency), vocal fold polyps (14 cold knife and 13 radiofrequency), and Reinke's oedema (two cold knife and one radiofrequency).

Operative procedure

All procedures were performed under general anaesthesia with the smallest and safest endotracheal Portex tube. A Karl Storz Kleinsasser laryngoscope and a Carl Zeiss microscope (Germany) were used in all cases. In cold knife microdissection, Karl Storz microsurgical instruments (Germany) were used for surgical intervention. In the radiosurgical group, a specially designed needle electrode (fashioned by the authors, Figure 1), connected to a radiofrequency

apparatus model Ellman Surgitron F.F.P.F4 MHz, USA, were employed. The power was adjusted to the fifth power grade in a fully filtered mode. The same surgical principles were applied in cold knife and radiofrequency for excision of vocal fold nodules, polyps and Reinke's oedema. Small vocal nodules and pedunculated polyps were grasped with a pair of fine forceps and excised at their base. Large nodules, diffuse polyps and Reinke's oedema were excised using a microflap technique with dissection and suction of the gelatinous materials.⁸ Excessive mucosa was then grasped and trimmed. All specimens were sent for histopathological diagnosis and the results were consistent with the diagnosis of benign superficial vocal fold lesions. The operative time was kept by an independent nurse and estimated from insertion to removal of the Kleinsasser laryngoscope. Figure 2 shows pre- and post-radiofrequency excision of bilateral vocal fold nodules.

Post-operative care

A policy of two days of complete voice rest, followed by two weeks of voice moderation was adopted. Smoking was prohibited for two weeks after surgery. Post-operative voice therapy was provided for all patients. Hydration and humidification were advised. Complications, smoothness of post-operative recovery, and administration of analgesia were reported.

TABLE I
VOICE EVALUATION IN THE COLD KNIFE GROUP IN THE FIRST FOLLOW-UP SETTING

Parameter	Pre-operative	Post-operative	P value
	Mean \pm SD (n = 25)	Mean \pm SD (n = 25)	
Visual analogue scale	8.56 \pm 1.08	1.24 \pm 0.43	< 0.001
G item of GRB scale	2.28 \pm 0.54	0.56 \pm 0.50	< 0.001
R item of GRB scale	1.88 \pm 0.60	0.12 \pm 0.33	< 0.001
B item of GRB scale	2.48 \pm 0.50	0.84 \pm 0.62	< 0.001
Jitter	0.72 \pm 0.23	0.21 \pm 0.08	< 0.001
Shimmer	4.62 \pm 1.73	1.75 \pm 0.36	< 0.001

Voice evaluation

A standard voice sample was obtained pre-operatively and in follow-up settings using a set of high-quality voice recordings in a sound-proof room. Samples were subjected to both perceptual and acoustic evaluation by three phoniatriests serving as judges. A simplified version of the GRBAS scale (GRB) consisting of G (grade), R (roughness), and B (breathiness) factors was adopted to assess hoarseness, using a four-point grading system (0 = normal, 1 = slight, 2 = moderate, 3 = extreme). To show the acoustic characteristics of the voice including 'jitter' and 'shimmer', voice samples were analysed using a computerized voice laboratory. On the other hand, a visual analogue scale (VAS) was used to assess the patient's own evaluation of the social acceptability of his or her voice. The patients were asked to rate his/her voice on a 10.0 cm line by marking a slash mark at a point they felt appropriate. A score of 0 indicated a totally acceptable voice and a score of 10 indicated a totally unacceptable voice. All the patients attended the first follow-up setting one month after surgery. Twelve patients were missed in the second follow-up setting which ranged between the third and ninth month after surgery with a mean of 4.8 (\pm 1.4) in the cold knife group and 5.3 (\pm 1.7) in the radiofrequency group. The phoniatriests and the patients were not aware of the procedure undertaken.

Statistical methods

In order to maintain exactly equal treatment numbers in both groups, randomization was done using random blocks. At the time of randomization, both the patient and the investigator were not aware of the group assignment. The analysis was done using the SPSS for Windows statistics software package. Data were expressed as mean \pm

standard deviation (SD). *P* values <0.05 were considered significant. Parametric tests such as *t*-test were applied for data that followed a normal distribution. Non-parametric tests such as the Mann-Whitney U test, Wilcoxon signed ranks test and chi-square test were applied for data that did not follow a normal distribution.

Results

Baseline data

No statistically significant difference between the cold knife and the radiofrequency groups was found in the baseline data of any of the following parameters: demographic characteristics, VAS and voice analysis.

Visual analogue scale

Both groups experienced a significant improvement in VAS after surgery ($p < 0.001$) (Tables I-IV). There was no statistical evidence for a significant difference between the cold knife and radiofrequency groups ($p > 0.05$). No significant difference was experienced between the first and second follow-up settings in the same group ($p > 0.05$).

Perceptual evaluation

A statistical improvement of voice perceptual parameters was noticed in both groups. The mean values of the GRB scale decreased significantly from the pre- to the post-operative levels ($p < 0.001$) (Tables I-IV). There was no evidence of a statistically significant difference in the degree of GRB scale improvement between the cold knife and radiofrequency groups ($p > 0.05$). No significant difference was experienced between the first and second follow-up settings in the same group ($p > 0.05$).

TABLE II
VOICE EVALUATION IN THE RADIOFREQUENCY GROUP IN THE FIRST FOLLOW-UP SETTING

Parameter	Pre-operative	Post-operative	P value
	Mean \pm SD (n = 25)	Mean \pm SD (n = 25)	
Visual analogue scale	8.96 \pm 0.89	1.32 \pm 0.48	< 0.001
G item of GRB scale	2.12 \pm 0.60	0.52 \pm 0.51	< 0.001
R item of GRB scale	2.01 \pm 0.57	0.16 \pm 0.37	< 0.001
B item of GRB scale	2.36 \pm 0.70	0.88 \pm 0.60	< 0.001
Jitter	0.64 \pm 0.22	0.22 \pm 0.07	< 0.001
Shimmer	4.37 \pm 1.64	1.61 \pm 0.43	< 0.001

TABLE III
VOICE EVALUATION IN THE COLD KNIFE GROUP IN THE SECOND FOLLOW-UP SETTING

Parameter	Pre-operative	Post-operative	P value
	Mean \pm SD (n = 20)	Mean \pm SD (n = 20)	
Visual analogue scale	8.70 \pm 1.12	1.30 \pm 0.47	< 0.001
G item of GRB scale	2.35 \pm 0.58	0.65 \pm 0.48	< 0.001
R item of GRB scale	2.10 \pm 0.45	0.15 \pm 0.36	< 0.001
B item of GRB scale	2.60 \pm 0.50	0.80 \pm 0.69	< 0.001
Jitter	0.78 \pm 0.22	0.22 \pm 0.08	< 0.001
Shimmer	5.00 \pm 1.71	1.76 \pm 0.35	< 0.001

Acoustic analysis

Both 'jitter' and 'shimmer' decreased significantly after surgery in both groups ($p < 0.001$), with no significant difference being noticed between the two groups ($p > 0.05$) (Tables I-IV). No significant difference was experienced between the first and second follow-up settings in the same group ($p > 0.05$).

Operative time

There was a tendency for a shorter operative time in the radiofrequency group, but this did not reach statistical significance ($p = 0.08$). The radiofrequency group showed a decrease of 17 per cent in the mean operative time when compared with the cold knife group.

Post-operative recovery and complications

There was no evidence of a statistically significant difference between the two groups regarding smoothness of post-operative recovery and administration of analgesia. No complications were encountered in both groups.

Discussion

Treatment of benign superficial vocal fold lesions essentially consists of voice therapy and phonosurgery. Voice therapy is the treatment of choice in vocal fold nodules. On the other hand, a substantial lack of consensus is present regarding the value of voice therapy in other benign vocal fold lesions. The principles of phonosurgery were established in the late 1960s and have undergone significant advances since Hirano's discovery of the layered microarchitecture of the lamina propria.⁹ Phonosurgery is not a cosmetic surgery of the vocal fold but is rather a functional surgery to restore or improve the voice. Surgical management must leave a clean surgical bed with no scarring

healing process. It must follow the lines of forces of the vocal folds, respecting the lamina propria and the basement membrane zones and preserving as much epithelium as possible. The current surgical procedures entail the use of cold knife, laser and videoendoscopic assisted instrumentations.¹ In a recent survey of current opinion and practice in the management of benign vocal fold lesions, cold knife instruments have been reported to be the safest and the most widely used. In addition it allows for tactile feedback and ability to apply counter-tension while operating. The laser has been preferred by one in five surgeons, with a concern that the added benefit of a relatively bloodless field is largely countered by the dissipation of heat into the delicate lamina propria.⁹ The laser creates a heat effect, especially, by using a large spot size and by shooting twice on the same spot. The first impact dehydrates the tissue, whereas the second carbonizes and tremendously increases the heat of the deep layer. Additional drawbacks of the laser are the increased cost and inherent risks such as laser fire and risks to operating room personnel.³ Videoendoscopic laryngeal surgery may be beneficial in patients with difficult laryngeal exposure or a contraindication for general anaesthesia.¹⁰

In this study, the procedure of microscopic radiosurgical management of benign superficial vocal fold lesions was presented and compared with conventional cold knife excision. The study did not reveal any significant detectable difference in clinical and voice evaluation outcomes. The tendency to a shorter operating time may be explained by the longer haemostatic time needed to control bleeding in some cases in the cold knife group, whereas the radiosurgical probe had an excellent haemostatic effect. Most authors have reported good results in dealing with benign superficial vocal fold lesions. Hormann *et al.*¹¹

TABLE IV
VOICE EVALUATION IN THE RADIOFREQUENCY GROUP IN THE SECOND FOLLOW-UP SETTING

Parameter	Pre-operative	Post-operative	P value
	Mean \pm SD (n = 18)	Mean \pm SD (n = 18)	
Visual analogue scale	9.10 \pm 0.92	1.33 \pm 0.49	< 0.001
G item of GRB scale	2.33 \pm 0.48	0.50 \pm 0.51	< 0.001
R item of GRB scale	2.16 \pm 0.51	0.22 \pm 0.42	< 0.001
B item of GRB scale	2.61 \pm 0.50	0.94 \pm 0.54	< 0.001
Jitter	0.68 \pm 0.22	0.23 \pm 0.07	< 0.001
Shimmer	5.02 \pm 1.41	1.63 \pm 0.46	< 0.001

compared carbon dioxide laser and conventional phonosurgery in 44 patients. The results four months after surgery showed an improvement of vocal function in both treatment groups when compared with the pre-operative findings. Benninger¹² conducted a prospective randomized trial comparing cold knife microdissection and microspot carbon dioxide laser in 37 patients. He concluded that both tools were excellent in the management of vocal nodules, polyps, cysts and Reinke's oedema. Omori *et al.*¹⁰ reported very satisfactory results using videoendoscopic laryngeal surgery and specially designed fine-tipped forceps and scalpels. Tsunoda *et al.*¹³ also designed detachable forceps to be used with flexible fibre-optic laryngeal surgery in cases where rigid laryngoscopy is contraindicated, reporting good post-operative results.

- **This randomized controlled study looks at the feasibility of radiosurgical excision of vocal fold lesions**
- **Patients undergoing radiosurgical treatment and 'cold knife' excision showed similar results in terms of voice quality**
- **Radiosurgery for vocal fold lesions combines the advantages of both cold knife and laser surgery, being easy, safe, precise and effective with excellent tactile and haemostatic properties**

Inherent in the introduction of a new surgical technique should be the assumption that the new technique offers a distinct advantage or at least no disadvantage over current treatment modalities. Radiophonosurgery combines the advantages of both laser and cold knife phonosurgery. It is a simple mini-invasive surgical procedure which does not require any safety precautions. The micro-sharp tip of the radiosurgical probe concentrates the radiofrequency energy, resulting in improved cutting and haemostasis precision and ensures the least amount of thermal damage to adjacent tissue. This induces no carbonization, less scarring and fast healing. It also allows excellent tactile feedback, and less pain and swelling. It cuts without exerting any pressure and minimizes risk of injury to laryngeal structures. In addition, it combines the potential for a short operating time with a cost effective machine. Further studies are warranted to discuss its indications and explore its use in different laryngeal pathologies.

Conclusion

Radiophonosurgery opens up a new therapeutic approach for patients with benign superficial vocal fold lesions. It combines the advantages of both cold knife and laser phonosurgery, being easy, safe, precise and effective with excellent tactile and haemostatic properties.

References

- 1 Johns MM. Update on the etiology, diagnosis, and treatment of vocal fold nodules, polyps, and cysts. *Curr Opin Otolaryngol Head Neck Surg* 2003;**11**:456–61
- 2 Zeitels SM. Premalignant epithelium and microinvasive cancer of the vocal fold: the evolution of phonomicrosurgical management. *Laryngoscope* 1995;**105**(3 Pt 2):1–51
- 3 Abitbol J, Abitbol P. Surgical management of non-neoplastic vocal fold lesions: laser versus cold knife excision. *Curr Opin Otolaryngol Head Neck Surg* 2000;**8**:514–23
- 4 Strong MS, Jako GJ. Laser surgery in the larynx. Early clinical experience with continuous CO₂ laser. *Ann Otol Rhinol Laryngol* 1972;**81**:791–8
- 5 Smith TL, Smith JM. Electrosurgery in otolaryngology - head and neck surgery: principles, advances, and complications. *Laryngoscope* 2001;**111**:769–80
- 6 Maddern BR. Electrosurgery for tonsillectomy. *Laryngoscope* 2002;**112**(8 Pt 2):11–13
- 7 Elsherief S, Elsheikh MN. Endoscopic radiosurgical posterior transverse cordotomy for bilateral median vocal fold immobility. *J Laryngol Otol* 2004;**118**:202–6
- 8 Matsuo K, Kamimura M, Hirano M. Polypoid vocal folds. A 10-year review of 191 patients. *Auris Nasus Larynx* 1983;**10**(suppl.):S37–45
- 9 Sulica L, Behrman A. Management of benign vocal fold lesions: a survey of current opinion and practice. *Ann Otol Rhinol Laryngol* 2003;**112**:827–33
- 10 Omori K, Shinohara K, Tsuji T, Kojima H. Videoendoscopic laryngeal surgery. *Ann Otol Rhinol Laryngol* 2000;**109**:149–55
- 11 Hormann K, Baker-Schreyer A, Keilmann A, Biermann G. Functional results after CO₂ laser surgery compared with conventional phonosurgery. *J Laryngol Otol* 1999;**113**:140–4
- 12 Benninger MS. Microdissection or microspot CO₂ laser for limited vocal fold benign lesions: a prospective randomized trial. *Laryngoscope* 2000;**110**(2 Pt 2):1–17
- 13 Tsunoda K, Kikkawa YS, Yoshihashi R, Sakai Y. Detachable forceps for flexible fibre-optic surgery: a new technique for phonosurgery in cases where rigid laryngoscopy is contraindicated. *J Laryngol Otol* 2002;**116**:559–61

Correspondence to:
Mr Sameh M Ragab,
PO Box 66482,
Bayan 43755, Kuwait.

Fax: 009655529012
E-mail: sragab@doctors.org.uk

Mr Sameh M Ragab takes responsibility for the integrity of the content of the paper.

Competing interests: None declared