

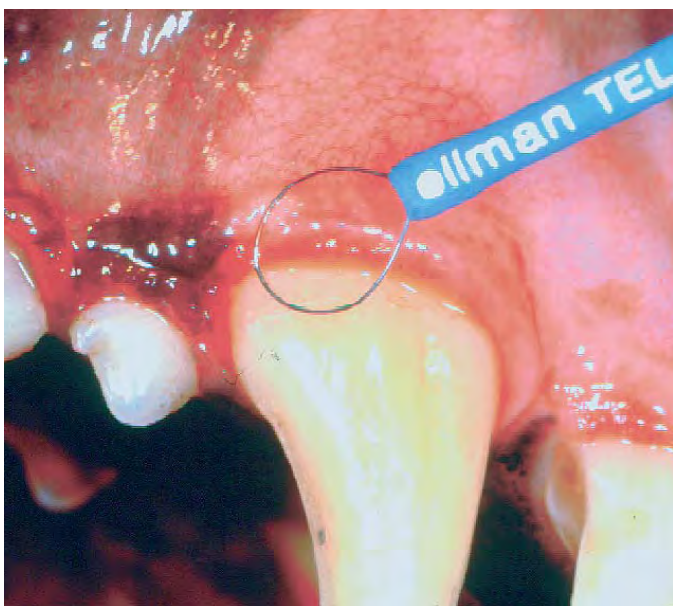


SMALL ANIMAL

# Radiosurgery has place in veterinary dentistry

DONALD H. DEFORGE, VMD, FAVD  
Contributing Author

**Q:** I have heard a lot about radiosurgery in human dentistry. How does it apply to animal dentistry? Is it safe?



**Figure 1:** The dental operator is performing a gingivoplasty using a radiosurgery unit electrode.

**A:** Radiosurgery is very safe and has multiple uses in veterinary dentistry. High frequency radio waves of 3.0-4.0 MHz produce a pressureless incision with minimal thermal and mechanical tissue trauma. With radiosurgery there is the virtual elimination of bleeding allowing a clear surgical field.

There are four radiosurgery waveforms used in dentistry. The fully filtered waveform, with minimal lateral heat, is used most frequently when incisions are close to bone. This waveform is used in biopsy, frenectomies, mucogingival surgery and the troughing procedure.

The troughing procedure is used for widening of the sulcus for a crown impression in sub-

gingival fixed prosthodontics.

The fully rectified waveform provides cutting with hemostasis.

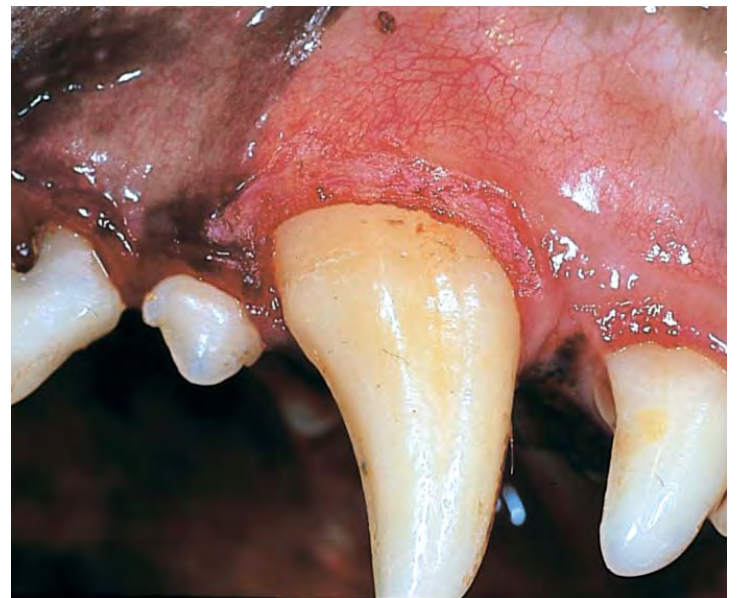With this waveform resultant tissue shrinkage and some lateral heat don't make it a choice when working near bone. It is used in gingivoplasty, epulis removal, and pericoronal flap removal.

The partially rectified waveform is used to produce hemostasis.

It should not be used for coagulation close to bone because of significant lateral heat and tissue shrinkage. The main uses are coagulation of soft tissue and desensitizing cementum and dentin with cervical erosions.

The final waveform, the fulguration waveform, produces a dehydrating effect as it causes the greatest amount of lateral heat. The spear shaped electrode is placed about 0.5 mm above the surface of the tissue. A spark is produced when the current is activated leading to superficial destruction and coagulation. It is also called the spark-gap technique and is frequently used for the destruction of fistulous tracts, destruction of cyst remnants and hemostasis in osseous surgery.

There are a plethora of radiosurgery electrode tips available. The straight wire, loop and ball are the three most commonly used.



**Figure 2:** With the gingivoplasty completed, the operator can use a "paintbrush" technique and a triangular electrode to reestablish normal gingival contour

The new bendable electrodes are a significant advantage in difficult to reach sites.

The triangular and loop shaped electrodes are commonly used in the paintbrush technique of gingivoplasty. Ellman International produces a Vari-tip® electrode. It has a tungsten cutting wire that

can be varied in length to make each incision case specific for controlled cutting depth.

In combination with a periodontal probe (subgingival crown preparations), the troughing procedure can be performed without penetrating the epithelial attachment.

Whether for periodontal surgery (gingivoplasty and flap surgery) or in prosthodontic (subgingival impressions) soft tissue preparation, radiosurgery is an invaluable tool.

## SUGGESTED READING

- Wiggs RB & Lobprise HB. *Veterinary Dentistry Principle and Practice*, Lippincott-Raven, 1997.
- Harty FJ. *Concise Illustrated Dental Dictionary*, 2nd Edition. Butterworth-Heinemann Ltd, 1994.
- Sherman JA. *Oral Radiosurgery—2nd Edition*. Martin Dunitz, 1997.
- Zetner K & Sherman J. Ellman International—Dento-Surg/TM 90 FFP Technical Bulletin. 1135 Railroad Ave., Hewlett, N.Y., 1997. (Reprint from *Veterinary Forum*, Jan. 1995)

Dr. DeForge, fellow of the Academy of Veterinary Dentistry, is a private practitioner with an on-site referral dental center at the Milford Veterinary Hospital in Milford, Ct. He also operates the Mobile Dental Referral Service for consultation, diagnosis and treatment of dental cases at practitioners' hospitals in Connecticut. DeForge authors *Veterinary Dentistry Report*, a newsletter that encapsulates common problems in dentistry and oral surgery faced by the general practitioner. He may be contacted at (203) 877-3221, FAX (203) 877-8301. □



Whether for periodontal surgery (gingivoplasty and flap surgery) or in prosthodontic (subgingival impressions) soft tissue preparation, radiosurgery is an invaluable tool. There are four radiosurgery waveforms used in dentistry. The fully filtered waveform, with minimal lateral heat, is used most frequently when incisions are close to bone. This waveform is used in biopsy, frenectomies, mucogingival surgery and the troughing procedure.